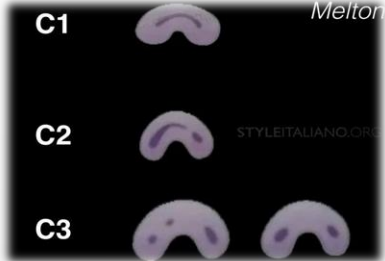


MANAGEMENT OF C-SHAPED CANAL IN MANDIBULAR THIRD MOLAR- A CASE REPORT



PRESENTED BY: DR RIYA PARWANI
GUIDED BY: DR SOUMYA SHETTY

