

Management Of Gingival Recession – BY Gingival Unit Transfer

DPU

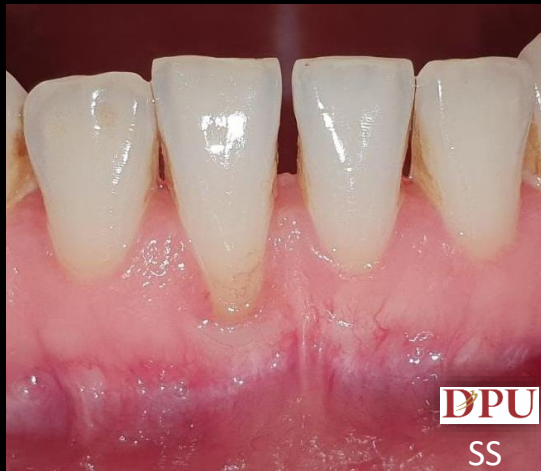Dr. D. Y. Patil Vidyapeeth, Pune
(Deemed to be University)

Operated by: Dr Sharath Shetty.

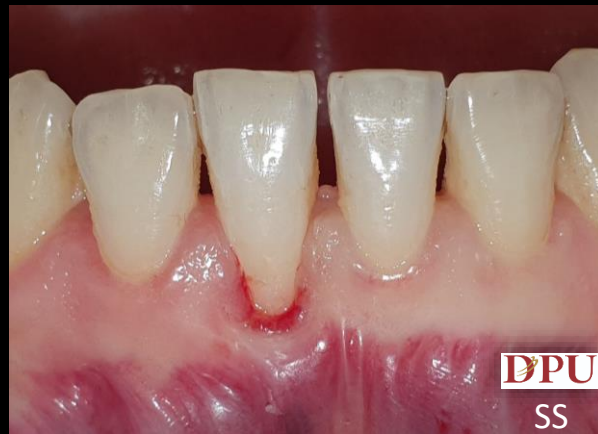Assisted by: Dr. Shrinivas Garje.

01 / 07 / 21

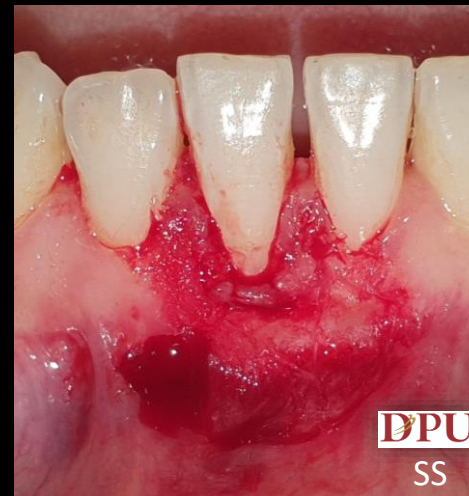Department of
Periodontology and oral
implantology.



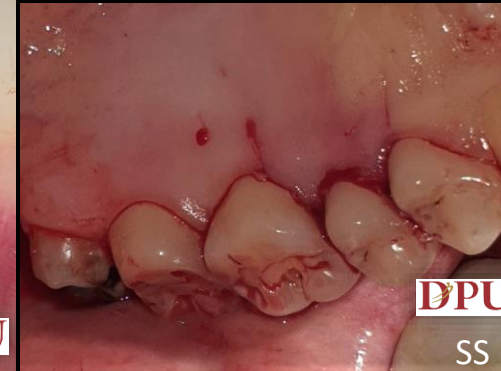PRE-OP: Miller's Class III recession/ Cairo RT2 w.r.t. 41



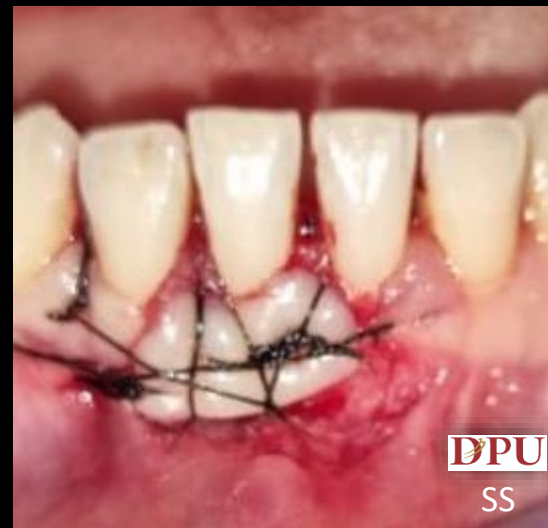Scaling and Root Planing



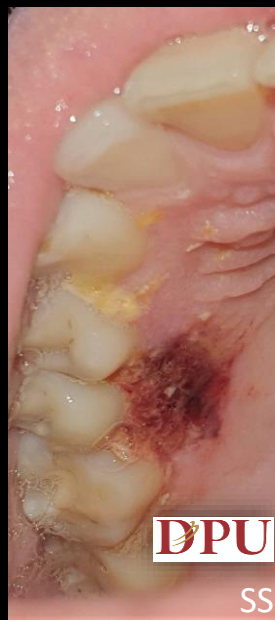Recipient Bed Preparation



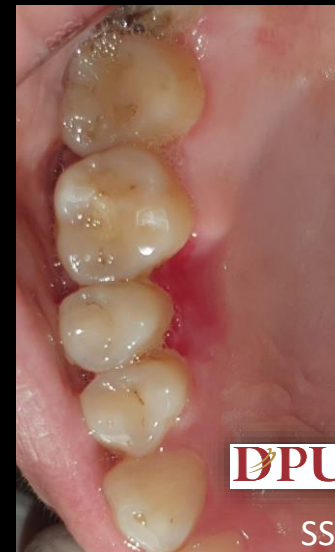Incisions For Harvesting the Graft



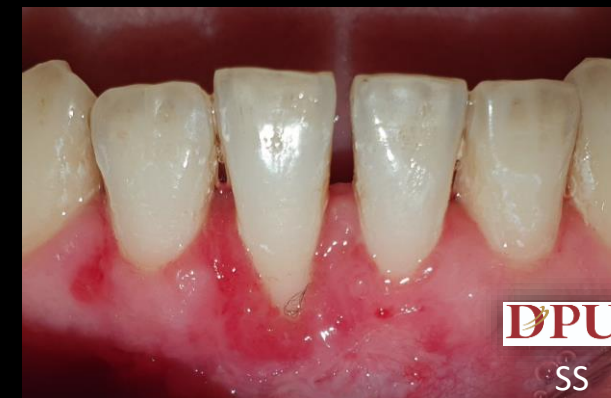Graft placed and sutured on recipient bed



1 week post-op donor site



1month post-op Recipient site

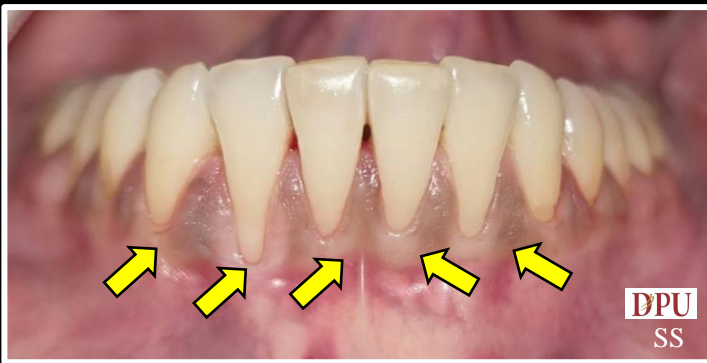

1 month post-op donor site

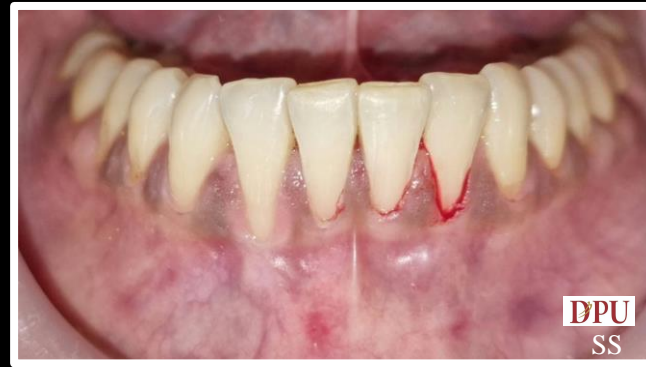CORONALLY ADVANCED FLAP USING TUNNEL TECHNIQUE WITH PRF



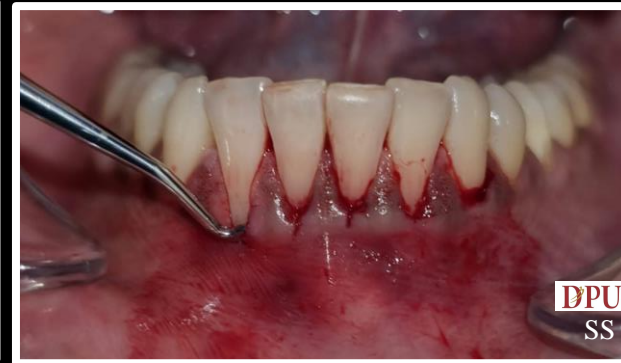Operated by: Dr Sharath Shetty
 Assisted by: Dr. Gopika Nair
 Operated on: 25 June 2021
 Department of Periodontology



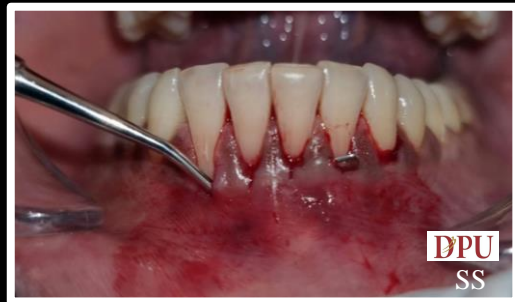Pre-Op: Miller's Class III recession/ Cairo RT2 wrt 31,32,33,41 and 42




Mechanical Root Planing With Curette And Diamond Bur and Chemical Root Conditioning With Tetracycline



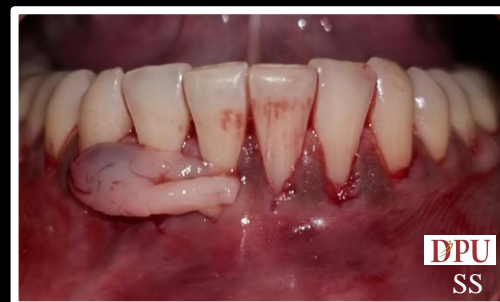Tunnel preparation wrt 31,32,33,41,42



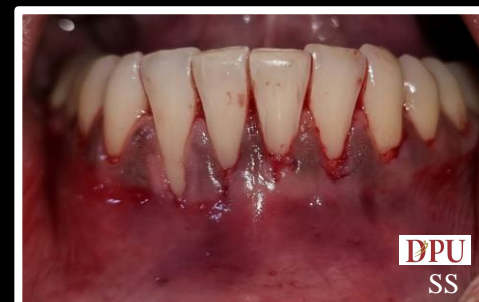Complete releasing of the tunnel



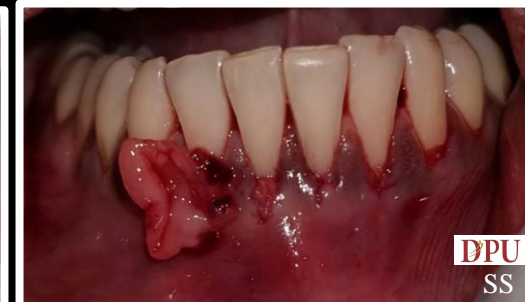PRF prepared with 20ml blood & placed on the choukran's box



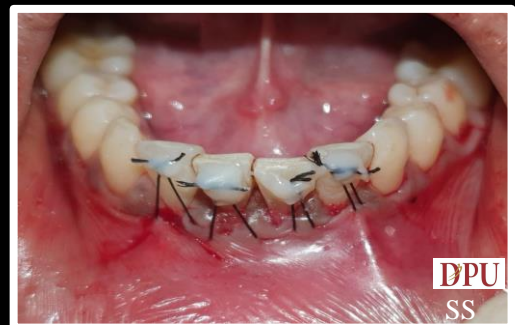Insertion of first PRF membrane



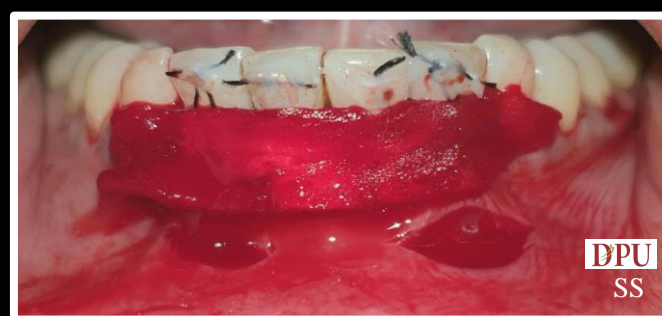Fullness of the tissues seen due to insertion of PRF membrane



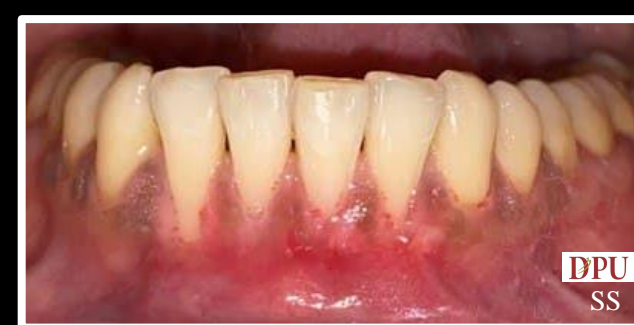Insertion of second PRF membrane



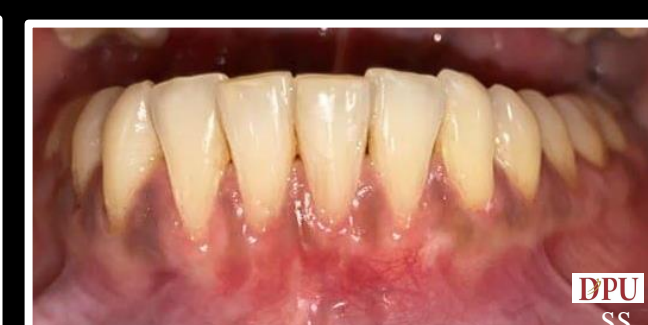Composite stops and suspensory sutures placed. Tension present at the site



Incisions given to release the tension on the flap Curaspon (absorbable gelatin sponge) placed at the surgical area



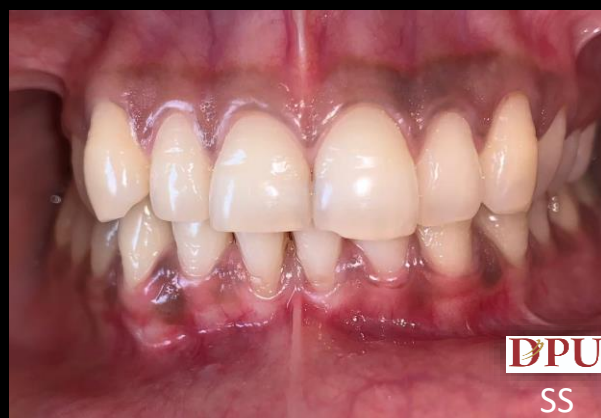Sutures removed and debonding of composite stops done after 14 days



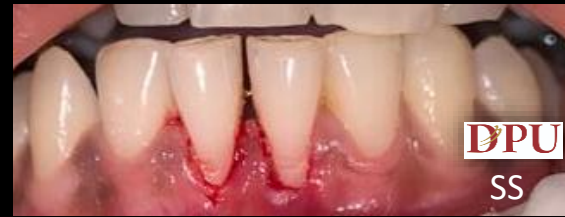Post-Op after 3 months

Management of Gingival Recession – BY Free Gingival Graft

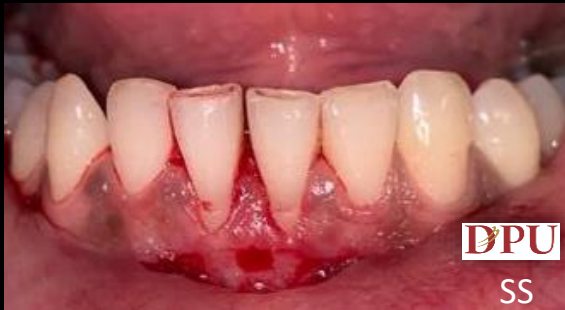Operated by: Dr D Gopalakrishnan.
Assisted by: Dr. Komal Ambilwade.
Department of Periodontology and oral implantology



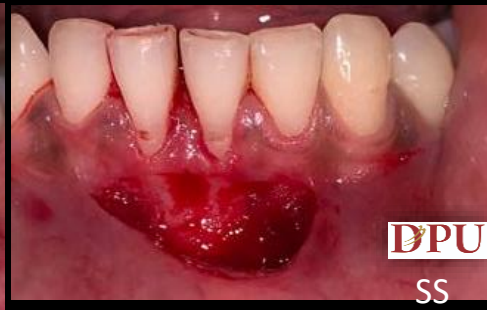Gingival recession



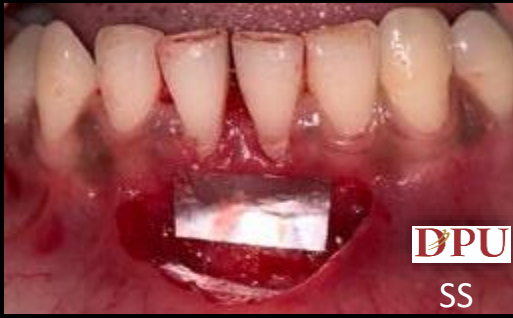Scaling & Root Planing



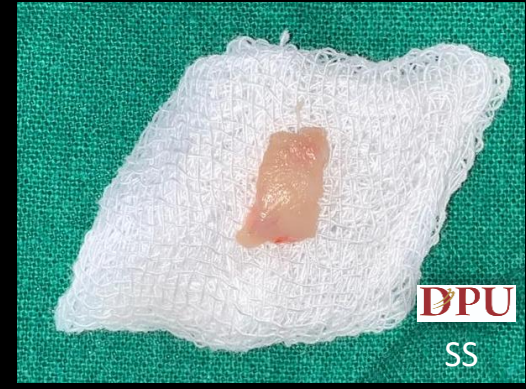Incision



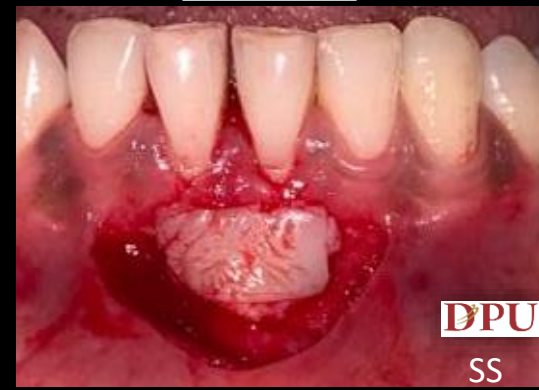Graft bed preparation



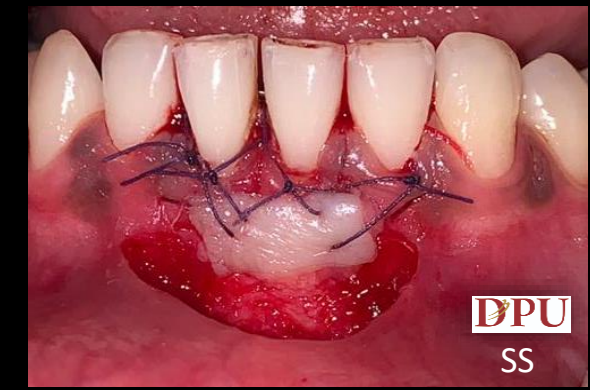Aluminum foil template
Measurement for grafting



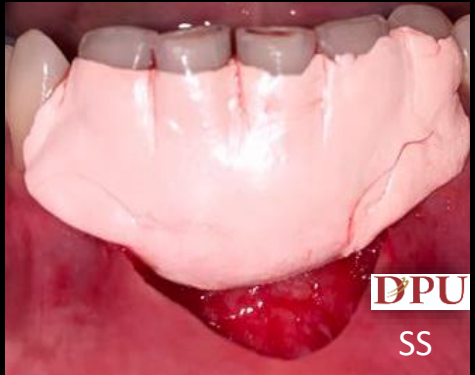Graft Harvested



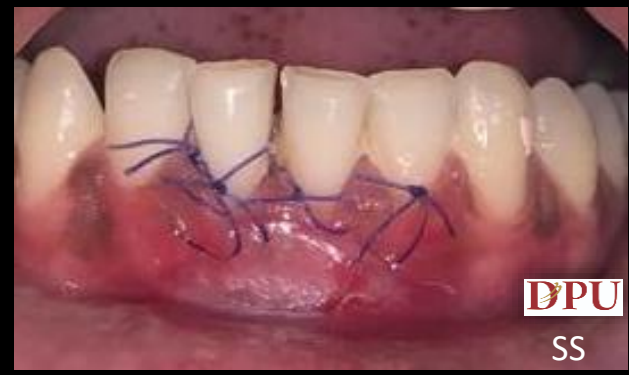Placement of Graft on Site



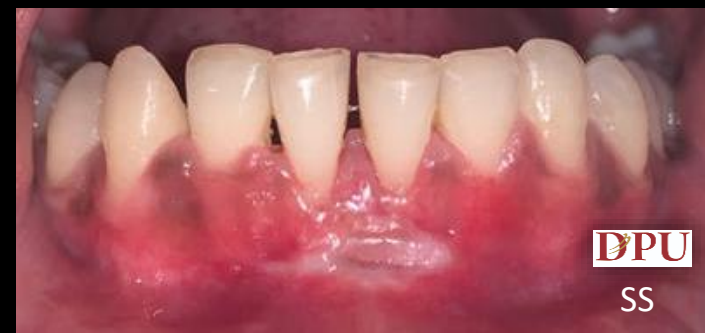Sutures



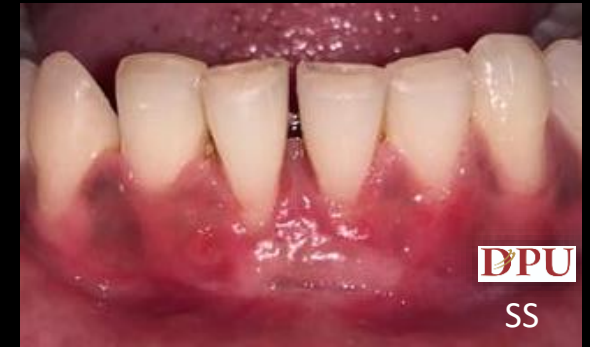Periodontal pack



7 Days post-operative



15 days post-operative



1 month post-operative