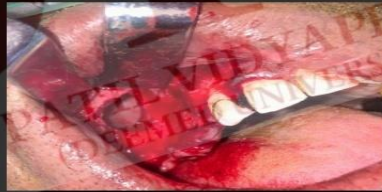
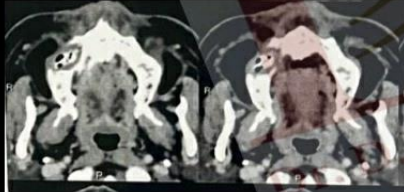
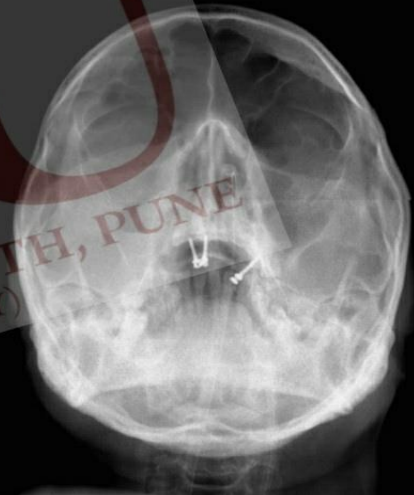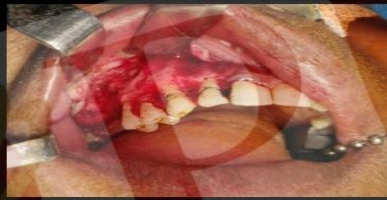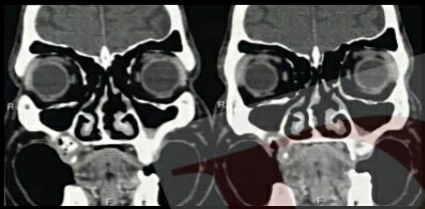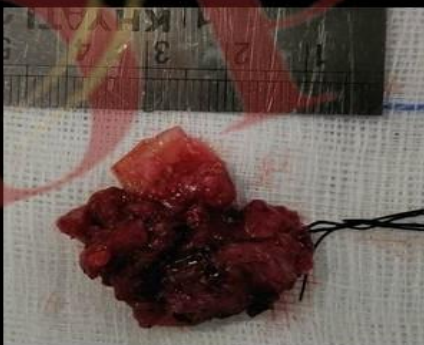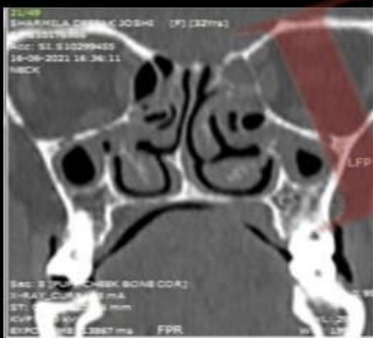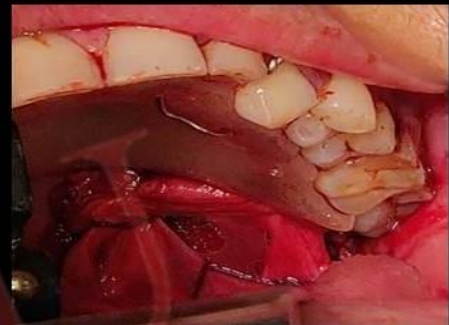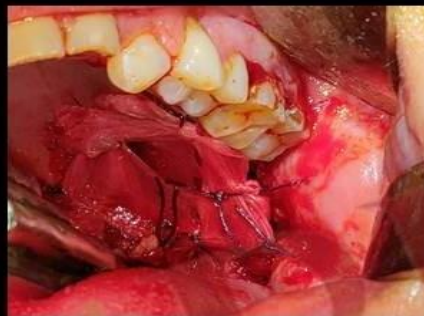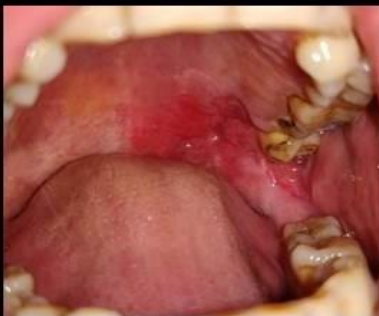DEPARTMENT OF ORAL AND MAXILLOFACIAL SURGERY

CASES JUNE – JULY 2021



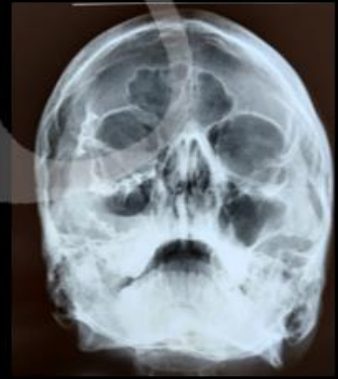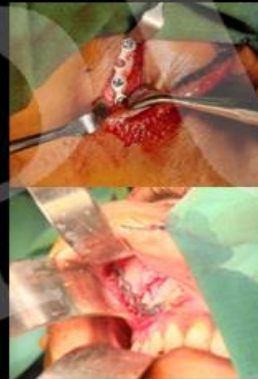
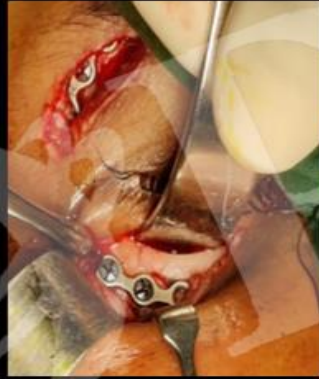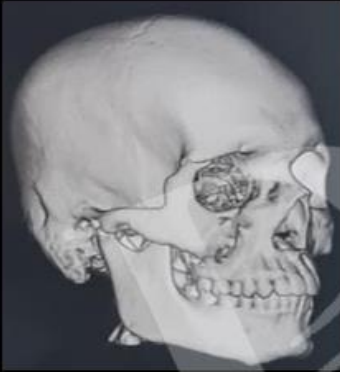DEPARTMENT OF ORAL AND MAXILLOFACIAL SURGERY CASES: JUNE - JULY 2021



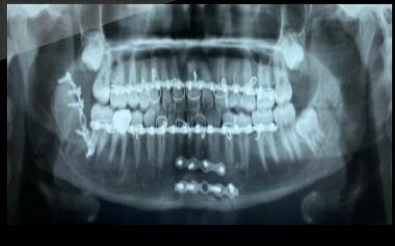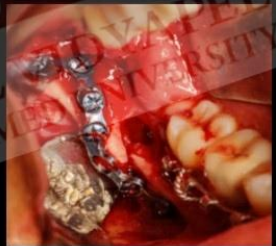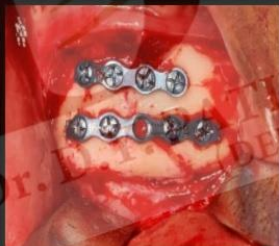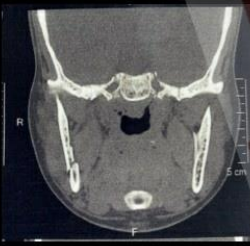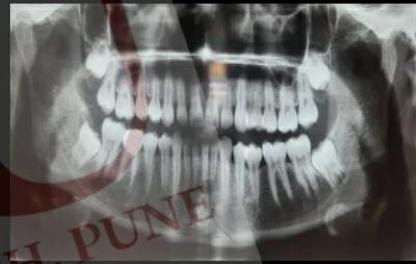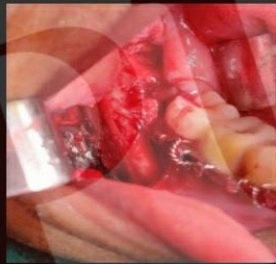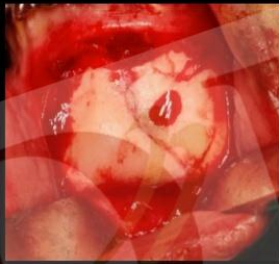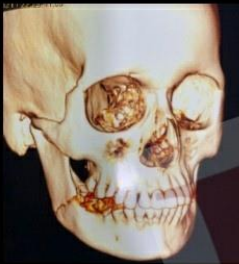Impression : Left palatal mucosal lesion; Wide excision:
Invasive moderately differentiated squamous carcinoma of palate.
Maximum depth of tumor invasion: 0.3cm.
All mucosal margins and base: Free of tumor.

Right buccal mucosal lesion; Excision:
Hyperplastic squamous mucosa. (Consistent with leucoplakia)
No e/o dysplasia or malignancy.

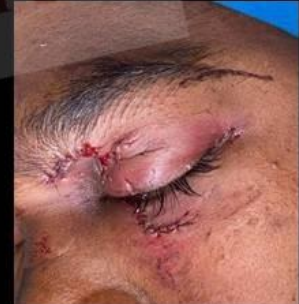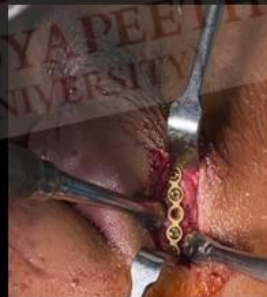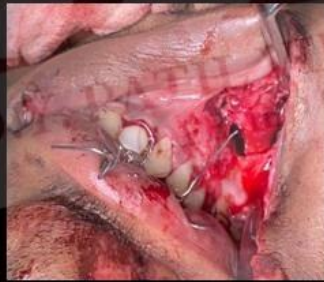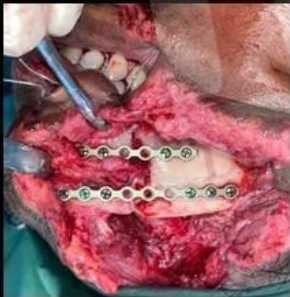
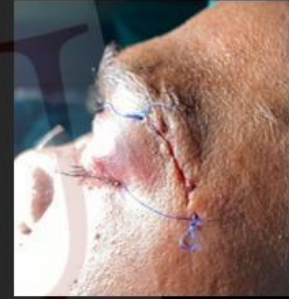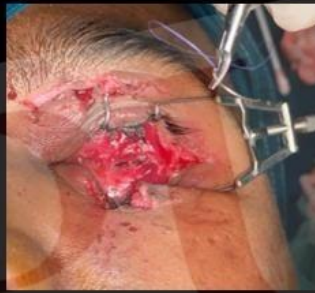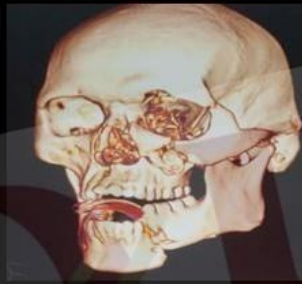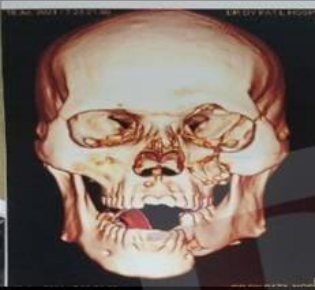DEPARTMENT OF ORAL AND MAXILLOFACIAL SURGERY: JUNE 2021



**DEPARTMENT OF ORAL AND MAXILLOFACIAL SURGERY
CASES JUNE – JULY 2021**



DEPARTMENT OF ORAL AND MAXILLOFACIAL SURGERY
CASES JUNE-JULY 2021



DEPARTMENT OF ORAL AND MAXILLOFACIAL SURGERY
CASES JUNE-JULY 2021

