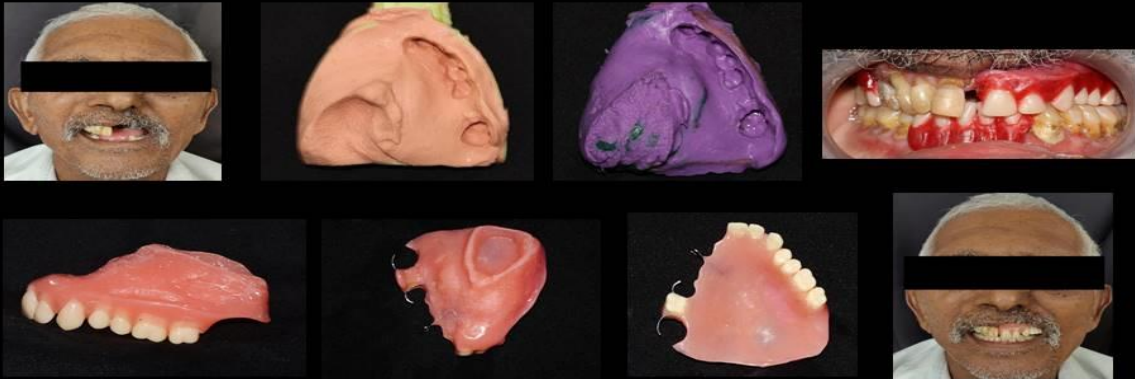


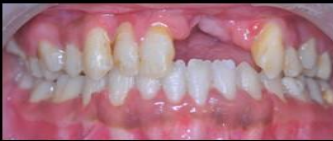# Interim Open Bulb Obturator



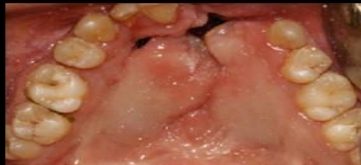Guided by: Dr. Amit Jagtap  
Dr. Varun Bhatt

## REHABILITATION OF A PATIENT WITH DEFECT WITH DEFINITIVE OBTURATOR

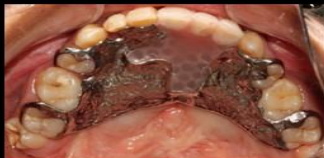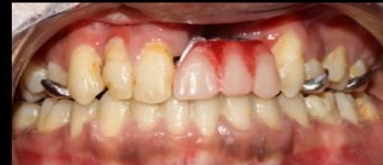Pre-op view



Mouth Preparation

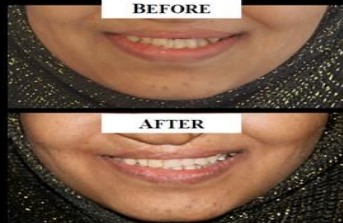

Try in



Final Prosthesis

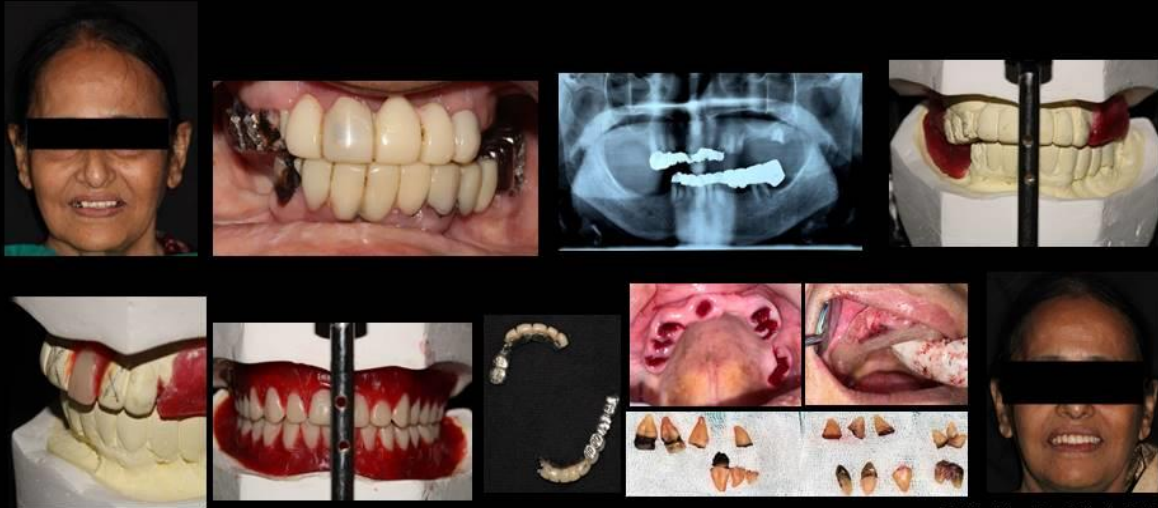BEFORE



AFTER

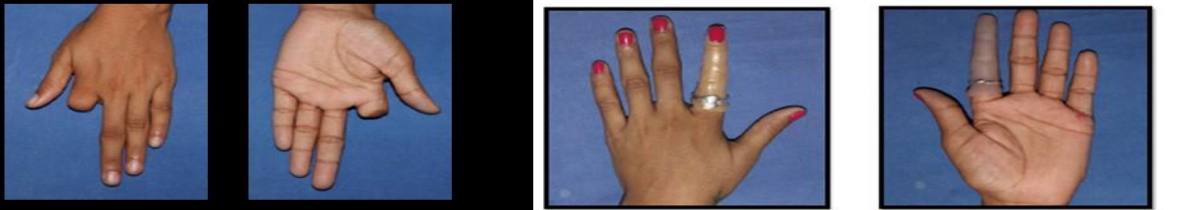Dr. Vaibhav Jathar  
Guided by- Dr. Amit Jagtap

# Interim Immediate Denture



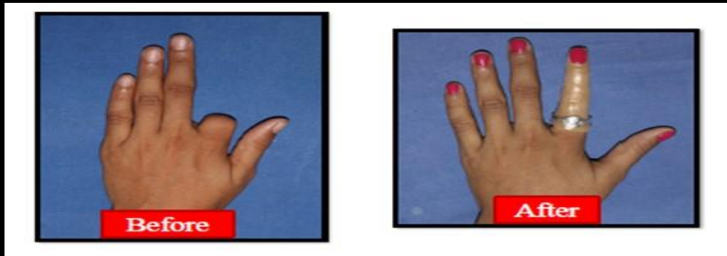
Guided by :Dr. Nilesh Bulbule  
Dr. Varun Bhatt

# FINGER PROSTHESIS



Pre-op view

Post-op view

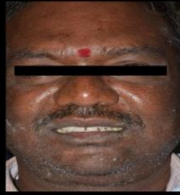

Before

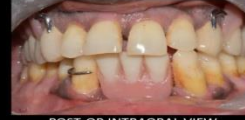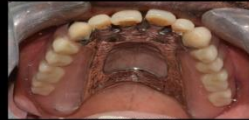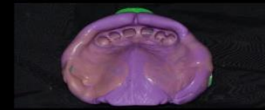
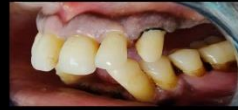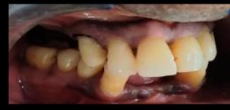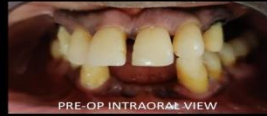After

Dr. Vedashree Natu  
Guided by- Dr. Nayana Anasane

REHABILITATION OF PARTIALLY EDENTULOUS MAXILLARY ARCH WITH  
CAST PARTIAL DENTURE OPPOSING CONVENTIONAL REMOVABLE PARTIAL DENTURE  
IN PARTIALLY EDENTULOUS MANDIBULAR ARCH

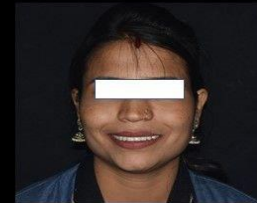
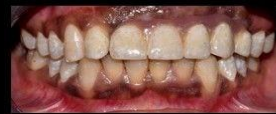
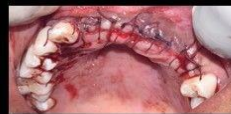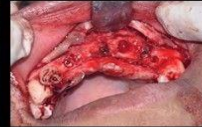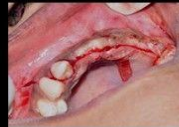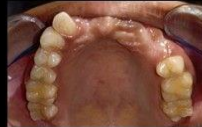DR. TRUNAYA BHATLEKAR  
GUIDED BY - DR. SIDDHARTH SWARUP



DENTAL IMPLANT CENTER

IMPLANT SUPPORTED FIXED PROSTHESIS IN THE ANTERIOR ESTHETIC REGION.



Guided By: Dr Siddharth Swarup  
Post Graduate: Dr Amit Nandi (Department of Prosthodontics)